

THE EFFECTS OF INTRACAMERAL ANESTHESIA ON THE CORNEAL ENDOTHELIUM IN RABBITS

Magda Salaheldin Abdelaziz and Raessa Abdeltawab Mohamed*
Ophthalmology and Histology* Departments, Faculty of Medicine,
Cairo University

INTRODUCTION

Newer methods of ocular anesthesia have emerged to complement the advanced techniques and instrumentation of modern - day cataract surgery. Local anesthesia has become preferable to general anesthesia for cataract surgery. The advantages of local anesthesia are well known and include : more rapid ambulation, the ability to perform the procedure as an outpatient, avoidance of complications associated with general anesthesia, and quicker surgery (**Patel et al., 1996**).

Methods of local anesthesia for cataract extraction include : retrobulbar, peribulbar, subconjunctival, and sub-Tenon application of local anesthetic solution (**Ducker et al., 1991**). Retrobulbar anesthesia has been associated with a number of potentially serious complications including inadvertent globe perforation, retrobulbar hemorrhage, orbital infection, central retinal artery occlusion, damage to the optic nerve, *intravascular or intrathecal injection*, postoperative diplopia and ptosis (**Morgan et al., 1988**). Peribulbar anesthesia eliminates the risk of optic nerve trauma, and lessens the chance of retrobulbar hemorrhage. However, the risk of globe perforation still remains (**Kimble et al., 1987**). Topical and intracameral anesthesia are new options for pain control in modern cataract surgery. Topical anesthesia has been shown to be a safe and effective alternative to retrobulbar and peribulbar anesthesia (**Duguid et al., 1995**). Topical anesthesia provides adequate anesthesia for phacoemulsification, with immediate recovery of visual acuity after surgery. However, the significant downfall of this technique lies in its failure to provide adequate motor and sensory anesthesia, when only topical drops are used. This may lead to an increased risk of intraoperative complications due to unrestricted eye movement and insufficient pain control. The lack of optic nerve blockade may also result in

intolerance of the microscopic light (Fukasaku and Marron, 1994; Kreshner, 1993). Subconjunctival and peribulbar anesthesia have been recommended as supplements to topical anesthesia. (Anderson, 1995).

Intracameral anesthesia has also been introduced as a possible method for providing additional anesthetic effect to topical anesthesia. Injection of the anesthetic agent into the anterior chamber is reported to be beneficial in reducing patient discomfort during surgery (Karp et al., 2001). Intracameral techniques have included the injection of preservative - free lidocaine hydrochloride 1% or preservative-free bupivacaine hydrochloride 0.5% into the anterior chamber prior to phacoemulsification. Since these drugs are not formulated for intraocular use, there is a concern about the efficacy and safety of this technique, particularly possible toxicity to the corneal endothelium (Karp et al., 2001).

Although clinical studies have claimed no adverse effects of this technique, adequate laboratory studies have yet to be performed to determine the possible untoward effects for intracameral anesthesia on the corneal endothelium (Kim et al., 1998).

The aim of this work was to evaluate the direct effect of intracameral injection of the commercially available lidocaine hydrochloride on the rabbits' corneal endothelium viability and ultrastructure.

MATERIALS AND METHODS

This study was done on 54 eyes of 27 pigmented rabbits. Their weight ranged between 1.25 and 2 kg.

A rabbit model was chosen because of the gross morphologic similarities between rabbit and human corneas. All animals were healthy and free of clinically detectable ocular abnormalities.

The rabbits were anesthetized using intramuscular injections of ketamine hydrochloride (35 mg / kg body weight) and xylazine 2% (5 mg / kg body weight).

The rabbits were divided into three groups, each group containing nine rabbits (18 eyes). An operating microscope was used; a wireless lid speculum was placed to separate the eyelids. The anterior chamber was entered in the superior temporal quadrant through paracentesis site using 27 gauge needle attached to one ml. tuberculin syringe. Half a milliliter of the following solutions was injected into the anterior chamber :

Group 1 :

Lactated Ringer's solution was injected (control group).

Group 2 :

1% lidocaine hydrochloride (xylocaine 1%) was injected, prepared by dilution of xylocaine 2% using lactated Ringer's solution.

Group 3 :

2% lidocaine hydrochloride (xylocaine 2%) was injected (the concentration available commercially).

The injections were done in both eyes of all rabbits. Great care was taken to avoid touching the corneal endothelium, iris or lens. A cotton tip applicator was pressed against the wound to prevent wound leak as the 27 gauge needle was withdrawn.

All animals were kept in the animal house in Kasr El-Aini Hospital, Cairo University. The animals were divided into 3 sets, each made of 9 rabbits (18 eyes), [3 rabbits (6 eyes) from each group]. The sets were sacrificed after 1 hour, 2 hours, and 3 days after the anesthetic injection. After death, the eyes were enucleated and the corneoscleral buttons were removed.

The corneal buttons were examined using light microscopy, after preparation of paraffin sections and staining with Hematoxylin and Eosin.

The corneal buttons were also examined using transmission electron microscope after putting the buttons in a fixative solution of 4% glutaraldehyde, then were put in phosphate buffer, then were transferred to buffered osmium tetroxide, then dehydrated and stained with uranyl acetate and lead citrate.

RESULTS

Light microscopy of the corneal endothelium of the eyes in group (1), (the control group), showed normal features after one hour from the injection of lactated Ringer's solution in all eyes. Examination of the eyes of the same group after two hours, showed transient and mild changes in the form of mild swelling of the endothelial cells. These changes disappeared after three days, and the endothelial cells returned to normal viability (Plate 1).

Transmission electron microscopy revealed normal endothelium one hour after injection. Few vacuolations appeared in the cytoplasm of the endothelial cells two hours after injection, and then the cells returned to normal three days after the injection.

tion (Plate 2).

In group (2), in which the eyes of rabbits were injected with 1% xylocaine, light microscopy of the corneal endothelium showed normal configuration, when examined one hour after injection. There was mild swelling of the nuclei accompanied with cytoplasmic vacuolations in most of the eyes two hours after the injection. These changes were reversible, and appeared only in few eyes after three days (Plate 3).

Transmission electron microscopy revealed, healthy endothelium 1 hour after injection. However, 2 hours following injection, there were some early nuclear manifestations of degeneration in the form of condensed peripheral chromation with interruption of the nuclear envelope, accompanied with cytoplasmic rarefaction in few corneas. Three days after injection, no abnormalities were detected (Plate 4).

In group (3), in which the eyes of rabbits were injected with 2% xylocaine (the concentration available commercially), light microscopy of the corneal endothelium showed swollen nuclei accompanied with cytoplasmic vacuolations, when examined one hour after injection, in most of the cases. These changes had increased after two hours from injection. Irregularities of the cell membrane appeared with fragmentation of the nuclei. These changes were persistent and even increased after three days from injection. There were separation and death of the cells. In all eyes of this group, stromal edema was also present (Plate 5).

Transmission electron microscopy revealed, swelling of the endothelial cells, with focal loss of microvilli, one hour after injection. Two hours after injection, there was marked cellular degeneration in the form of degenerated and fragmented nuclei which appeared electronically dense, with rarefaction of the cytoplasm and ill-defined organelles. These nuclear and cytoplasmic degenerations were persistent and even exaggerated in all eyes three days after injection (Plate 6).

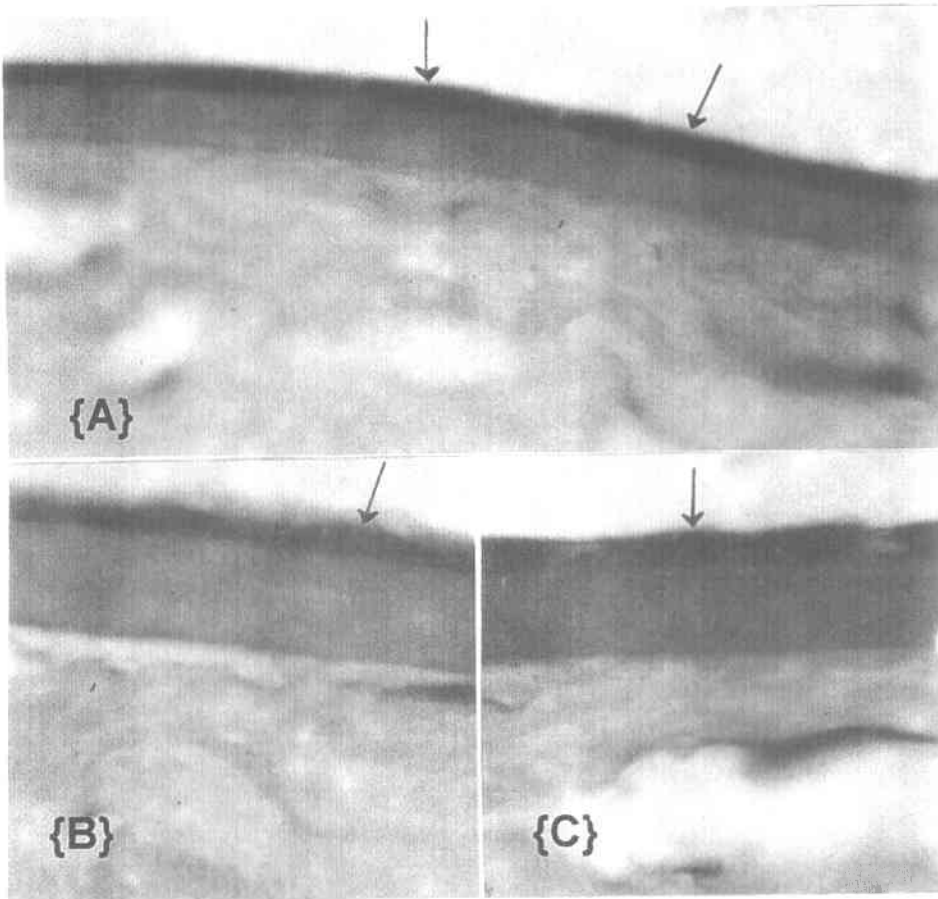


Plate (1) :Light photomicrographs of endothelial cells of rabbits' corneas injected intracamerally with Ringer's solution (control group). (H & E x 1000)

Fig. (1 - A) :Showing normal appearance of corneal endothelial cells one hour, after injection of Ringer's solution into the anterior chamber. The endothelial cells appear flat with flat healthy nuclei and thin intact cytoplasm (arrows).

Fig. (1 - B) :Showing mild edematous endothelial cells, with swollen nuclei, two hours after injection (arrow).

Fig. (1 - C) :Showing corneal endothelial cells after three days from injection, the endothelial cells start to return to its normal features with disappearance of edema (arrow).

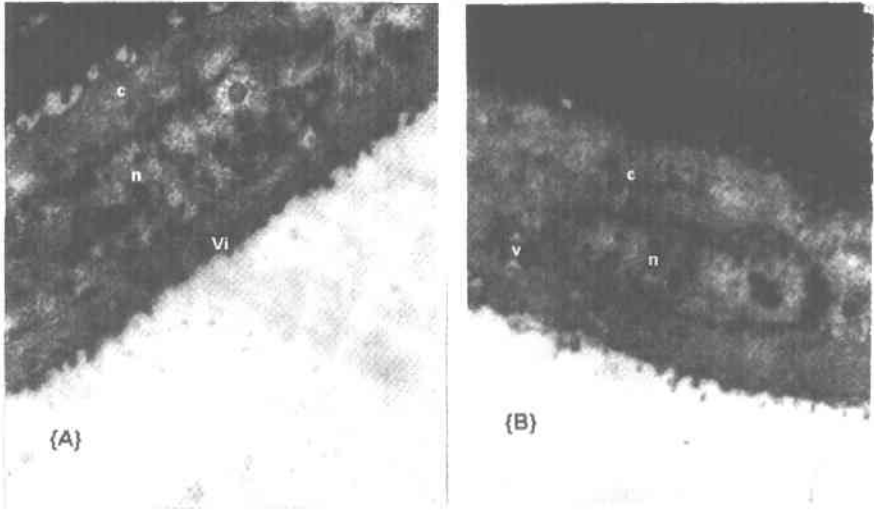


Plate (2) :Transmission electron micrograph of corneal endothelial cells of rabbits' corneas injected intracamerally with Ringer's solution (control group).
Fig. (2 - A) :Showing normal healthy nucleus (n), normal cytoplasm (c), and microvilli (Vi), one hour, after injection of Ringer's solution into the anterior chamber. (x 4000)
Fig. (2 - B) :Showing slightly swollen nucleus (n), edematous cytoplasm (c), in addition to the presence of few vacuoles (v), two hours after injection. (x 3000)

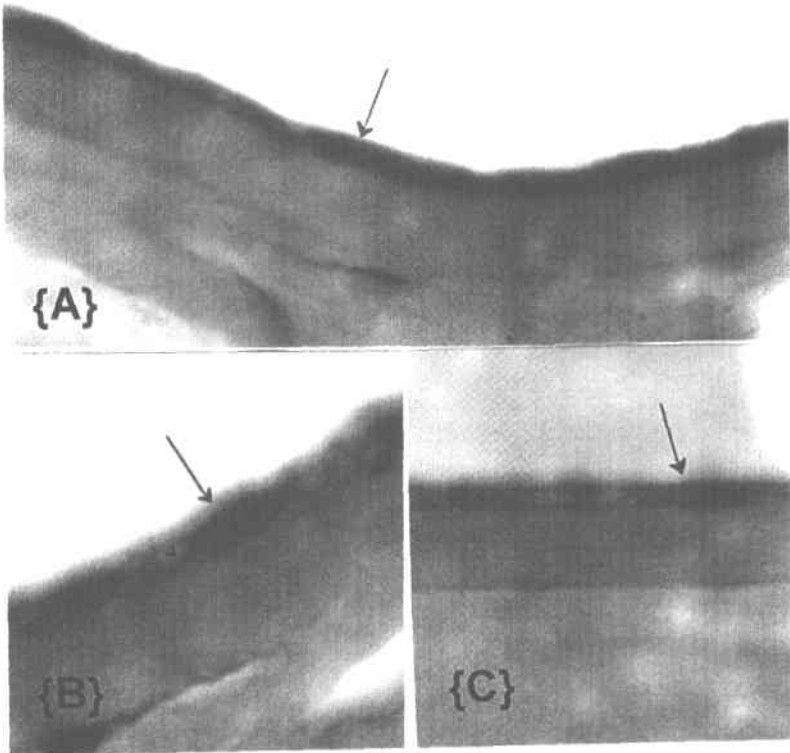


Plate (3) :Light photomicrographs of endothelial cells of rabbits' corneas injected intracamerally with 1% lidocaine Hcl. (H & E x 1000)

Fig. (3 - A) :Showing healthy endothelial cells (arrow) one hour after injection.

Fig. (3 - B) :Showing edematous endothelial cells and swollen nuclei (arrow) two hours after injection, with the appearance of small cytoplasmic vacuoles (v).

Fig. (3 - C) :Three days after injection the previous changes disappeared and the endothelial cells become normal (arrow).

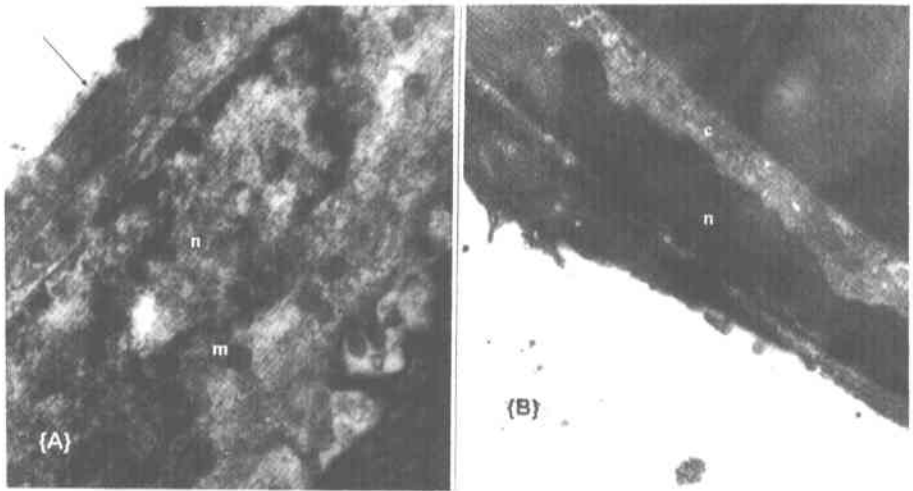


Plate (4) :Transmission electron micrograph of corneal endothelial cells of rabbits' corneas injected intracamerally with 1% lidocaine Hcl.

Fig. (4 - A) :Two hours after injection, the endothelial cells showing early nuclear degeneration with condensed peripheral chromatin (margination) with interruption of the nuclear envelop (n) and swollen mitochondria (m). (x 3000)

Fig. (4 - B) :Three days after injection, the endothelial cells showing normal nucleus (n) and normal cytoplasm (c). (x 2000)

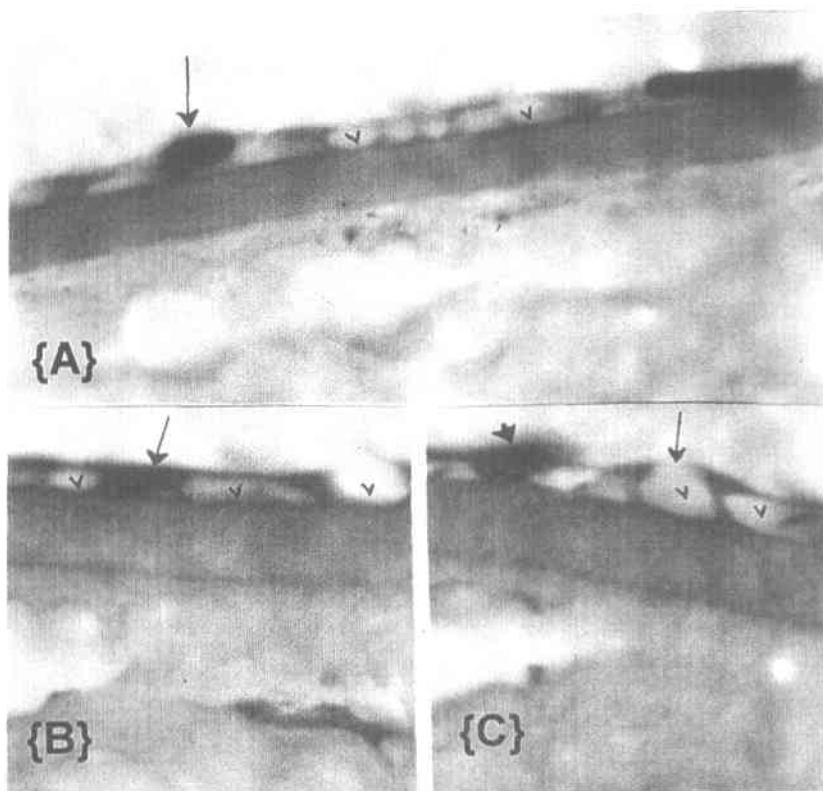


Plate (5) :Light photomicrographs of endothelial cells of rabbits' corneas injected intracamerally with 2% lidocaine Hcl. (H & E x 1000)

Fig. (5 - A) :One hour after injection, the endothelial cells are edematous, and the nuclei are condensed (arrow). The cytoplasm showing multiple vacuoles (v).

Fig. (5 - B) :Two hours after injection, most of the endothelial cells showed degenerated cytoplasm with large vacuoles (v) that destructed the cell wall. The nuclei are pyknotic and shrunken (arrow).

Fig. (5 - C) :Three days after injection, the endothelial cells are completely occupied with large sized vacuoles (v), and the nuclei are fragmented (arrow head).

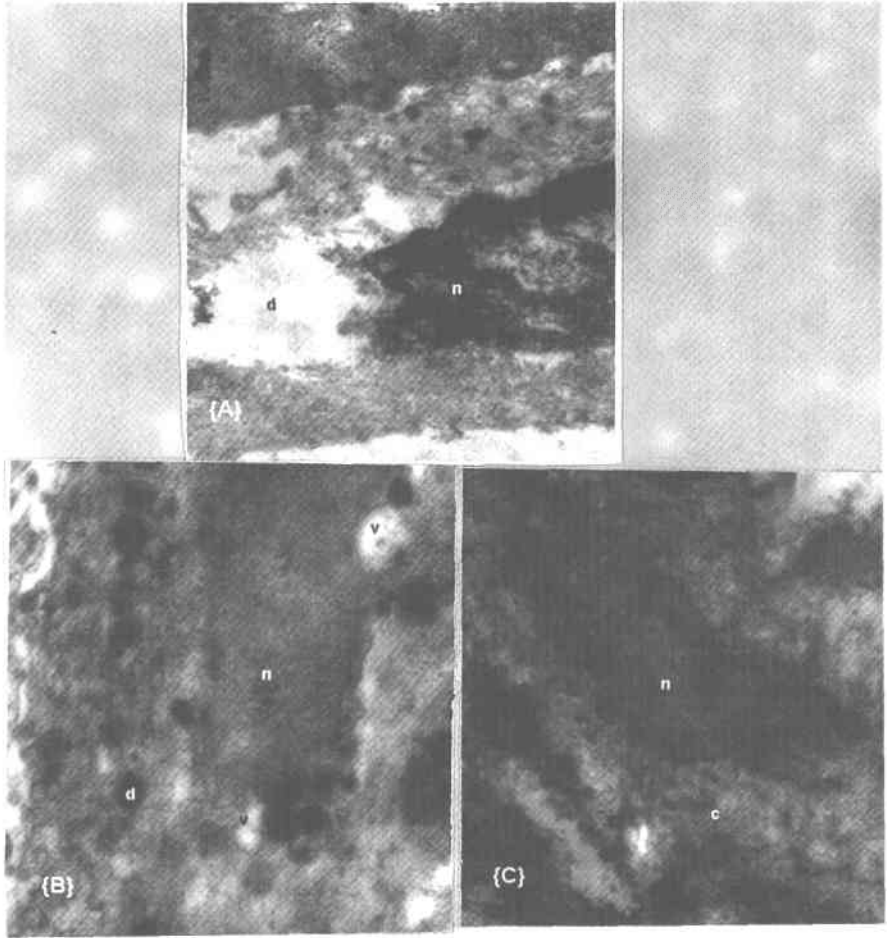


Plate (6) :Transmission electron micrographs of corneal endothelial cells of rabbits' corneas injected intracamerally with 2% lidocaine Hcl.

Fig. (6 - A) :One hour after injection, the endothelial cells are swollen with patchy cytoplasmic degeneration (d) and the nuclei begin to disintegrate (n). (x 6000)

Fig. (6 - B) :Two hours after the injection, the endothelial cells show degenerated and irregular nuclei (n). The cytoplasm has multiple dense bodies, which are most probably lysosomes (d) and many vacuoles of different sizes (v). (x 6000)

Fig. (6 - C) :Three days after injection, the nuclei of the endothelial cells are degenerated, fragmented and appeared electronically dense (n). The cytoplasm is highly rarified and full of degenerated ill-defined organelles. (x 6000)

DISCUSSION

Although topical anesthesia has been shown to be equally effective as retrobulbar anesthesia for cataract surgery, the concern of intraoperative pain and patients' discomfort led the ophthalmic surgeons to experiment with various techniques for providing supplemental anesthesia (Patel et al., 1996). Most of the topical anesthetic agents used in ophthalmic practice, appear to have the same duration of action on the ocular surface, which is approximately 15 - 30 minutes. If cataract surgery will take longer time, supplemental anesthesia should be considered (Judge et al., 1997).

A peribulbar or even retrobulbar anesthesia can be added. However, this might generate unwanted external pressure on an open globe. Additional anesthetic drops can be added or intracameral supplementation can be considered. If the latter two options are chosen, the surgeons need to be concerned about the possibility of endothelial toxicity from any anesthetic agent that enters or is injected inside the eye (Judge et al., 1997).

Increasing numbers of ophthalmologists are using intracameral anesthesia to supplement the topical block. They may repeat the injection or add additional anesthetic agent to the irrigating solution to keep the patient comfortable. It was reported that intracameral anesthesia decreased pain at various points during surgery and after surgery (Duguid et al., 1995; Patel et al., 1996; Gills et al., 1997; Martin et al., 1998). The introduction of intracameral lidocaine as an adjunct to topical anesthesia for routine cataract extraction has begun without laboratory evaluation and safety studies on the corneal endothelium. The technique involves the injection of 0.1 - 0.5 ml of 1% of unpreserved lidocaine through an anterior chamber paracentesis site after administering topical anesthesia and before entering the eye. After viscoelastic is injected, the corneal wound is constructed and capsulorrhexis is performed. Phaco is initiated. For additional anesthetic effect, intracameral lidocaine injection of the same dose is repeated through the paracentesis site (Kim et al., 1998). While lidocaine is the most common used anesthetic agent for intracameral anesthesia, some surgeons have tried variations of the technique by using different dosages and concentrations of lidocaine, different anesthetic agents (as tetracaine and bupivacaine), and different delivery methods (as with irrigating solution) with comparable success (Kim et al., 1998).

This study tested the possible affection of rabbits' corneal endothelium using different concentrations of lidocaine HCl. Lidocaine HCl used in this study was preserved with methyl paraben (1 mg / ml), since the unpreserved solution was not

commercially available. The rabbit model was used in this study due to gross morphological similarity between rabbit and human corneas, the lower cost, and the general familiarity of the medical community with it. However, the rabbit corneal endothelium may regenerate after injury, in contrast to human endothelium in which the recovery after insult occurs by growing in size and migration of endothelial cells (Oslen and Davanger, 1984). However, the specimens in this study were examined after three days maximally which is insufficient duration for endothelial regeneration which starts seven to ten days after injury (Oslen and Davanger, 1984).

In the current study, no viscoelastic agent was used, and the anesthetic solution injected into the anterior chamber was not washed out or diluted as in actual surgery. These conditions allowed studying the worst-case scenario, to detect the maximum toxic effects that might result from the contact between the anesthetic agent and the corneal endothelium. In this study, lidocaine HCl was preserved with methyl paraben (1 mg / ml). The results showed that the use of 1% lidocaine HCl was associated with insignificant changes. Two hours after injection, minimal pathological changes were detected. These changes were reversible and disappeared after three days.

These results agreed with the results of other studies (Kim et al., 1998; Heuermann et al., 2002). Kim et al. (1998) evaluated the effect of preservative free lidocaine 1% on the corneal endothelium of human and rabbit corneas perfused with either lidocaine 1% or a control solution. Both human and rabbit corneas had transient reversible edema that disappeared rapidly (Kim et al., 1998). It was also reported that, the long-term postoperative endothelial cell course showed that topical anesthesia with an intracameral injection of unpreserved lidocaine 1% is a safe alternative to peribulbar anesthesia (Heuermann et al., 2002).

On the other hand, in this study injection of 2% lidocaine was associated with marked damage of the rabbits' corneal endothelium. These changes were evident in the specimens examined one hour after injection, in the form of swelling of the nuclei, vacuolations of the cytoplasm, and even beginning of necrosis of the cells. These changes were more obvious two hours after injection, in the form of nuclear fragmentation with cytoplasmic vacuolations. In addition, transmission electron microscopy revealed, more progressive and irreversible changes after three days.

These results also agreed with the results of other studies. It was reported that preservative free lidocaine was injected intracamerally in concentrations of 0.02%, 0.2% and 2%. Scanning electron microscopy revealed no abnormal findings in the eyes injected with either 0.02% or 0.2%, but the eyes injected with lidocaine 2% showed irregular hexagonal endothelial cells and significant loss of microvilli

(Kadonosono et al., 1998). Eggeling et al. (2000) exposed porcine corneas to preservative free lidocaine Hcl 1%, 5% and 10% for 60 minutes. Lidocaine 1% in contact with the endothelium for 60 minutes did not cause any significant corneal endothelial damage. However, significant endothelial loss was observed with lidocaine 5% and 10% (Eggeling et al., 2000).

It was also reported that, intracameral injection of 0.5% tetracaine Hcl did not produce any significant corneal changes in rabbits. However, injection of 4% lidocaine Hcl, 0.75% bupivacaine Hcl, and 0.5% proparacaine Hcl produced significant corneal thickening and opacification (Judge et al., 1997).

With respect to both the experimental and clinical use of intracameral lidocaine, close attention must be paid to the specifics of the anesthetic agent used. Lidocaine is manufactured by a number of companies in varying concentrations, and with different vehicles and preservatives. These vehicles and preservatives themselves can induce cytotoxic changes to the endothelium (Kim et al., 1998). It was reported that, intracameral injection of bupivacaine Hcl 0.75%, which was preserved with methyl paraben (1 mg / ml), resulted in significant rabbits' corneal endothelial toxicity as assessed by pachymetry and corneal clarity. Injection of 1 : 10 dilution of the same agent failed to produce any significant changes in corneal thickness or clarity (Judge et al., 1997). On the other hand, other anesthetic agents as proparacaine and tetracaine are only available in their preservative form. The preservative is benzalkonium chloride (0.01%). Injection of benzalkonium chloride into the anterior chamber at concentrations of 0.025% and 0.05% had been found to cause irreversible corneal edema (Britton et al., 1976). However, intracameral injection of 0.5% preserved tetracaine Hcl did not produce any significant corneal changes in rabbits. On the other hand, injection of 0.5% preserved proparacaine Hcl produced significant corneal thickening and opacification (Judge et al., 1997).

There is some evidence of possible retinal toxicity, specifically electroretinographic changes following intracameral injection of lidocaine or bupivacaine. These changes were reported to be transient and dose dependent (Karp et al., 2001).

In conclusion, the results of this study showed that, lidocaine 1% has no harmful effects on the corneal endothelium of rabbits; higher concentrations can be associated with endothelial toxicity. It is recommended that, the minimal amount and concentration of intracameral anesthesia to be used based on the surgeon's surgical technique and the patient needs. Further studies are required in humans to study the effect of intracameral anesthesia particularly in cases of abnormal corneal endothelium.

SUMMARY

Intraocular anesthesia has the potential to become a popular and wide spread supplementary technique used in phacoemulsification. It may allow the surgeons to make the conversion to phaco easier. Surgeons also can start broadening patient criteria, making patients more eligible for topical anesthesia. Intracameral anesthesia also may prove beneficial in complicated cases, involving iris prolapse or vitreous loss, in which topical anesthesia alone may be inadequate. Therefore, the effects of intracameral lidocaine on the corneal endothelium as well as the specifications of lidocaine used deserve particular attention. The growing use and popularity of intracameral lidocaine will demand proper knowledge of these specifications and the potential effects on the endothelium before wide spread clinical use.

This study aimed at evaluating the effect of intracameral lidocaine on the rabbit corneal endothelium. This study included 54 eyes of 27 pigmented rabbits. These eyes were divided into three groups. In the first group, lactated Ringer's solution was injected into the anterior chamber, and was considered as a control. In the second and third groups, 1% and 2% lidocaine were injected into the anterior chamber. Corneas were examined after one hour, two hours and three days using light microscopy and transmission electron microscopy. Endothelial degenerations were prominent in the eyes injected with 2% lidocaine, while minimal reversible changes were noticed in the eyes injected with 1% lidocaine.

In conclusion, lidocaine 1% has no harmful effects on the corneal endothelium of rabbits; higher concentrations can be associated with endothelial toxicity. While short-term studies seem to indicate the safety of 1% lidocaine, there are still many questions, about the long-term effect on the corneal endothelium as well as the possibility of retinal toxicity. It is recommended that, the minimal amount and concentration of intracameral anesthesia to be used based on the surgeon's surgical technique and the patient needs. Further studies are required in humans to study the effect of intracameral anesthesia particularly in cases of abnormal corneal endothelium.

REFERENCES

1. Anderson, C.J. (1995) : Combined topical and subconjunctival anesthesia in cataract surgery. *Ophthalmic Surg.* **26** : 205 - 208.

2. Britton, B.; Hervey, R. and Kasten, K. (1976) : Intraocular irritation evaluation of benzalkonium chloride in rabbits. *Ophthalmic Surg.* 7 : 46 - 55.
3. Ducker, J.S.; Belmont, J.P. and Benson, W.E. (1991) : Inadvertent globe perforation during retrobulbar and peribulbar anesthesia. Patient characteristics, surgical management, and visual outcome. *Ophthalmology* 98 : 519 - 526.
4. Duguid, I.G.; Claone, C.M. and Thamby-Rajah, Y. (1995) : Topical anesthesia for phacoemulsification surgery. *Eye*, 9 : 456 - 459.
5. Eggeling, P.; Pleyer, U.; Hartmann, C. and Rieck, P.W. (2000) : Corneal endothelial toxicity of different lidocaine concentrations. *J. Cataract Refract Surg.* 26 : 1403 - 1406.
6. Fukasaku, H. and Marron, J.A. (1994) : Pinpoint anesthesia : a new approach to local ocular anesthesia. *J. Cataract Refract Surg.* 20 : 468 - 471.
7. Gills, J.P.; Cherchio, M. and Raanan, M.G. (1997) : Unpreserved lidocaine to control discomfort during cataract surgery, using topical anesthesia. *J. Cataract Refract Surg.* 23 : 545 - 550.
8. Heuermann, T.; Hartmann, C. and Anders, N. (2002) : Long-term endothelial cell loss after phacoemulsification : peribulbar anesthesia versus intracameral lidocaine 1% : a prospective randomized clinical trial. *J. Cataract Refract Surg.* 28 : 639 - 643.
9. Judge, A.J.; Najafi, K.; Lee, D.A. and Miller, K.M. (1997) : Corneal endothelial toxicity of topical anesthesia. *Ophthalmology.* 104 : 1373 - 1379.
10. Kadonodono, K.; Ito, N. and Yazama, F. (1998) : Effect of intracameral anesthesia on the corneal endothelium. *J. Cataract Refract Surg.* 24 : 1377 - 1381.
11. Karp, C.L.; Cox, T.A.; Wagoner, M.D. and Ariyasu, R.G. and Jacob, D.S. (2001) : Intracameral anesthesia. A report by the American Academy of Ophthalmology. *Ophthalmology.* 108 : 1704 - 1710.
12. Kim, T.; Holley, G.P.; Lee, J.H.; Brocker, G. and Edelhauser, H.F. (1998) : The effects of intracameral lidocaine on the corneal endothelium. *Ophthalmology.* 105 : 125 - 130.
13. Kimble, J.A.; Morris, R.E.; Witherspoon, C.D. and Fiest, R.M. (1987) : Globe perforation from peribulbar injection. *Arch Ophthalmol.* 105 : 749.
14. Kreshner, R.M. (1993) : Topical anesthesia for small incision self-sealing cataract surgery. A prospective evaluation of the first 100 patients. *J. Cataract Refract Surg.* 19 : 290 - 292.

15. **Martin, R.G.; Miller, J.D. and Cox, C.C. (1998)** : Safety and efficacy of intracameral injections of unpreserved lidocaine to reduce intraocular sensation. *J. Cataract Refract Surg.* **24** : 1136 - 1144.
16. **Morgan, C.; Schatz, H. and Vine, A.K. (1988)** : Ocular complications associated with retrobulbar injections. *Ophthalmology.* **95** : 660 - 665.
17. **Oslin, E.G. and Davanger, M. (1984)** : The healing of rabbit corneal endothelium. *Acta Ophthalmol.* **62** : 769 - 807.
18. **Patel, B.C.K.; Burns, T.A.; Cranall, A.; Shomaker, S.T.; Pace, N.L.; Van Ered, A. and Clinch, T. (1996)** : A comparison of topical and retrobulbar anesthesia for cataract surgery. *Ophthalmology.* **103** : 1196 - 1203.

تأثير حقن المخدرات الموضعية داخل الخزانة الأمامية للعين
على الخلايا المبطنة لقرنية الأرانب

ساجدة صلاح الدين عبد العزيز - رئيسة عبد التواب محمد*

قسم طب وجراحة العيون وقسم الهستولوجى* - كلية الطب - جامعة القاهرة

يستخدم المخدر الموضعى بكثرة أثناء اجراء العمليات الجراحية بالعين ، ومن الطرق الشائعة حقن هذا المخدر خلف الحجاج ولقد اثبتت بعض الدراسات ان هذه الطريقة لها بعض المضاعفات التى تؤثر على نجاح العملية وقوة الابصار . ومن الطرق الحديثة للتخدير الموضعى أثناء اجراء العمليات الجراحية بالعين هى استخدام القطرات المخدرة الموضعية وكذلك حقن المواد المخدرة داخل الخزانة الامامية للعين خاصة أثناء اجراء عملية المياه البيضاء عن طريق تفتيت العدسة بواسطة الموجات فوق الصوتية .

ولقد تم اجراء هذا البحث لدراسة تأثير المخدر الموضعى (الليدوكاين) على الخلايا المبطنة للقرنية فى حالة حقنه داخل العين . ولقد أجريت الدراسة على ٢٧ من الأرانب تم تقسيمهم إلى ثلاث مجموعات ، وقد تم حقن المجموعة الأولى (المجموعة الضابطة) بمحلول لبنات رنجر وتم حقن المجموعتين الثانية والثالثة بمحلول الليدوكاين ١٪ و ٢٪ .

ولقد تم اخذ القرنيات وفحصها بواسطة الميكروسكوب الضوئى وكذلك بواسطة الميكروسكوب الالكترونى وذلك بعد ساعة واحدة ثم ساعتين ثم ثلاثة أيام بعد حقن المخدر الموضعى .

ولقد تبين من نتيجة الفحص الميكروسكوبى للعينات أن الليدوكاين ١ ٪ لم يؤدي إلى تغيرات جوهريية فى الخلايا المبطنة للقرنية ، أما الليدوكاين ٢ ٪ أدى إلى حدوث تلف شديد للخلايا المبطنة للقرنية فى جميع العينات .

وقد أمكن استنتاج أن الليدوكاين ١ ٪ يمكن استخدامه بطريقة آمنة وحققه داخل الخزانة الأمامية للعين مع القطرات المخدرة الموضعية خاصة أثناء إجراء عمليات المياه البيضاء بطريقة تفتيت العدسة بواسطة الموجات فوق الصوتية .

مجلة التشريح المصرية ، ٢٦ (٢) ، يوليو ٢٠٠٣